



Head and Neck Associates of Orange County, Inc.

An Incorporated Medical Group

Head & Neck Surgery

Pediatric & Adult Otolaryngology

Facial Reconstructive Surgery

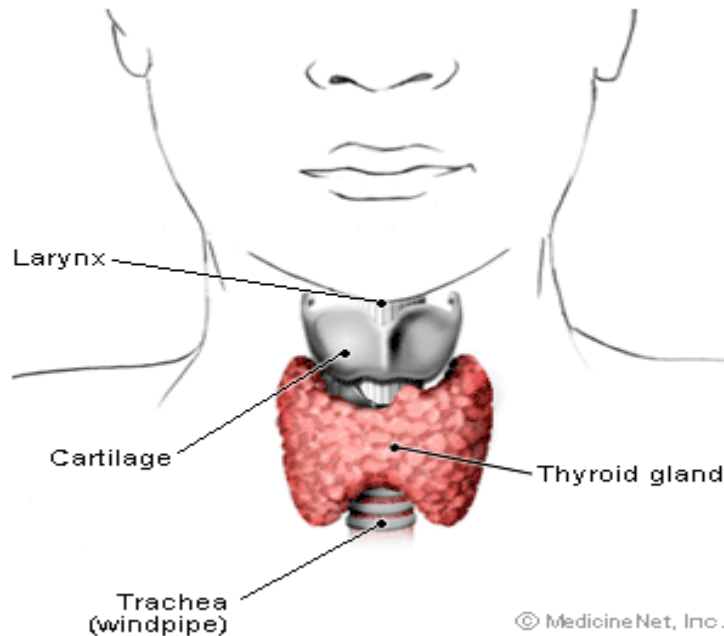
Thyroid Nodules and Thyroid Cancer

- [Introduction to thyroid nodules](#)
- [What is the prevalence of thyroid nodules and cancer?](#)
- [What are the symptoms of thyroid nodules?](#)
- [What are the types of thyroid nodules?](#)
- [How are thyroid nodules diagnosed?](#)
- [What is the treatment of thyroid nodules?](#)
- [What are the types of thyroid cancer?](#)
- [What causes thyroid cancer?](#)
- [Can thyroid cancer be detected early?](#)
- [What are symptoms of thyroid cancer?](#)
- [How is thyroid cancer diagnosed?](#)
- [What treatment is there for thyroid cancer?](#)
- [Thyroid Nodules At A Glance](#)
- [Thyroid cancer At A Glance](#)

Introduction to thyroid nodules

The term "thyroid nodule" refers to any abnormal growth that forms a lump in the thyroid gland.

The thyroid gland is located low in the front of the neck, below the Adam's apple. The gland is shaped like a butterfly and wraps around the windpipe or trachea. The two wings or lobes on either side of the windpipe are joined together by a bridge, called the isthmus, which crosses over the front of the windpipe.



A thyroid nodule can occur in any part of the gland. Some nodules can be felt quite easily, while others can be hidden deep in the thyroid tissue or located very low in the gland where they are difficult to feel.

What is the prevalence of thyroid nodules and cancer?

These days, with modern imaging studies such as ultrasound (US), computerized tomography (CT), and magnetic resonance imaging (MRI), more and more thyroid nodules are being found incidentally. This means the nodules are found during studies that are being done for reasons other than examination of the thyroid gland. It is estimated that 4-8% of adult women and 1-2% of adult men have thyroid nodules that can be felt on physical examination, but closer to 30% of women have nodules detectable by ultrasound. In fact, the diagnosis of a thyroid nodule is the most common endocrine problem in the United States.

Although the majority of thyroid nodules are benign (not cancerous), about 10% of nodules do contain cancer. Therefore, the primary purpose for evaluating a thyroid nodule is to determine whether cancer is present.

What are the symptoms of thyroid nodules?

The vast majority of thyroid nodules do not cause symptoms. However, if the cells in the nodules are functioning and producing thyroid hormone on their own, the nodule may produce signs and symptoms of too much thyroid hormone (hyperthyroidism). A small number of patients complain of pain at the site of the nodule that can travel to the ear or jaw. If the nodule is very large, it can compress the esophagus or trachea and cause difficulty swallowing or shortness of breath. In rare instances, a patient may complain of hoarseness or difficulty speaking because of compression of the larynx (or voice box).

What are the types of thyroid nodules?

Thyroid nodules may be single or multiple. A thyroid gland that contains multiple nodules is referred to as a multinodular goiter. If the nodule is filled with fluid or blood, it is called a thyroid cyst. If the nodule produces thyroid hormone in an uncontrolled manner without regard to the body's needs, the nodule is referred to as autonomous. This type of nodule may cause signs and symptoms of too much thyroid hormone or hyperthyroidism, as mentioned above. Occasionally, patients with a thyroid nodule may have too little thyroid hormone or hypothyroidism. This is most often seen when the hypothyroidism is due to Hashimoto's thyroiditis, an inflammatory, autoimmune disease of the thyroid gland.

The most common types of noncancerous, single thyroid nodules are colloid nodules or follicular adenomas. Another type of benign nodule that may be seen is called a Hurthle cell adenoma. Only a minority of nodules are cancerous. Cancerous nodules are classified by the types of malignant thyroid cells they contain. These cell types include papillary, follicular, medullary, or poorly differentiated (anaplastic) cells. The prognosis for the patient depends largely on the cell type and how far the cancer has spread by the time it is discovered.

In addition to thyroid cancer of the cell types mentioned, thyroid nodules may contain lymphoma, a cancer of the immune system. Cancer from other sites, such as breast and kidney, also can spread (metastasize) to the thyroid gland.

The cause of most thyroid nodules is not known. In certain cases, a lack of iodine in the diet can cause the thyroid gland to develop nodules. There also are certain genes that may be involved in the development of nodules in some individuals.

How are thyroid nodules diagnosed?

Thyroid nodules usually are discovered by the doctor on a routine physical examination of the neck. Occasionally, a patient may notice a nodule as a small lump in their neck when looking in the mirror. Once a nodule is discovered, a physician will carefully evaluate the nodule.

History. The doctor will need to take a detailed history, evaluating both past and present medical problems. If the patient is younger than 20 or older than 70 years of age, there is an increased likelihood that a nodule is cancerous. Similarly, if there is any history of radiation exposure (it was actually a standard treatment to apply radiation to the head and neck in the 1950's to treat acne!), difficulty swallowing, or a change in the voice, the nodule is more likely to be cancerous. Although women tend to have more thyroid nodules than men, the nodules found in men are more likely to be cancerous. Despite its value, the history cannot differentiate benign from malignant nodules. Thus, many patients with risk factors uncovered in the history will have benign lesions, while others without risk factors for malignant nodules may still have thyroid cancer.

Physical examination. The physician should determine if there is one nodule or many nodules, and what the rest of the gland feels like. If the nodule is fixed to the surrounding tissue (it is not movable), the probability of cancer is higher. In addition, the physical exam should include a search for any abnormal lymph nodes in the nearby area that may suggest the spread of cancer. In addition to evaluating the area of the thyroid, the physician should look for any signs of gland malfunction, such as an overproduction or underproduction of thyroid hormone (hyperthyroidism and hypothyroidism).

Blood tests. Initially, blood tests should be done to assess the function of the thyroid. These tests include the thyroid hormones, T3 and T4, and the hormone that stimulates the thyroid gland to produce thyroid hormone, called thyroid stimulating hormone (TSH). Elevated thyroid hormones and a low TSH suggest hyperthyroidism. Reduced thyroid hormones and a high TSH suggest hypothyroidism. A blood test called antithyroid peroxidase antibodies is useful in diagnosing autoimmune thyroiditis, for example, Hashimoto's thyroiditis. If surgery is likely to be considered for treatment, it is strongly recommended that the physician also determine the blood level of thyroglobulin. Thyroglobulin is a protein for carrying thyroid hormones in the blood stream, and it is only produced in the thyroid gland. Thus, if a gland is completely removed, thyroglobulin levels fall. If thyroglobulin levels start to climb after surgery, there is concern that the cancer may have recurred, either close to the site where the thyroid was removed or elsewhere in the body.

Ultrasonography. While evaluating the thyroid gland, a physician may order an ultrasound examination of the thyroid. The ultrasound examination can:

- Detect nodules that are not easily felt
- Determine the number of nodules and their sizes
- Determine if a nodule is solid or cystic
- Be used to assist in obtaining tissue from the thyroid gland or nodule with a fine needle

Despite its value, an ultrasound cannot determine whether a nodule is benign or cancerous.

Radionuclide scanning. Radionuclide scanning with radioactive chemicals is another imaging technique a physician may use to evaluate a thyroid nodule. The normal thyroid gland accumulates iodine from the blood and uses it to make thyroid hormones. Thus, when radioactive iodine (I 123) is administered orally or intravenously to an individual, it accumulates in the thyroid and causes the gland to "light up" when imaged by a nuclear camera (a type of Geiger counter). The rate of accumulation gives an indication of how the thyroid gland and any nodules are functioning. A "hot spot" appears if a part of the gland or a nodule is producing too much hormone. Non-functioning or hypo-functioning nodules appear as "cold spots" on scanning. A cold nodule has a risk of cancer that is higher than a normally or hyper-functioning nodule. Cancerous nodules are more likely to be cold because cancer cells are abnormal and don't accumulate the iodine as well as normal thyroid tissue.

Fine needle aspiration. A fine needle aspirate (FNA) of a nodule, a type of biopsy, is the most common direct way to determine what types of cells are present in the thyroid gland and in nodules. The needle is very small, and while the procedure is simple and can be done in a doctor's office, anesthetic usually is injected into the tissues traversed by the needle. Fine needle aspiration is possible if the nodule is easily felt. If the nodule is more difficult to feel, fine needle aspiration can be performed under the guidance of ultrasound. The needle is inserted into the thyroid gland or the nodule and cells are withdrawn. Usually, several samples are taken in order to give the best chance of detecting abnormal cells. The cells are then examined by a pathologist under a microscope. The value of fine needle aspiration is dependent on the experience of the physician performing the procedure as well as the pathologist reading the specimen.

Diagnoses that can be made from fine needle aspiration include:

- **Benign thyroid tissue** (non-cancerous), which can be consistent with Hashimoto's thyroiditis or a colloid nodule or cyst. This result is obtained in about 60% of biopsies.
- **Cancerous tissue** (malignant), consistent with the diagnosis of papillary, follicular, or medullary cancer. This result is obtained in about 5% of biopsies. The majority are papillary cancers.
- **Suspicious biopsy**, showing a follicular adenoma. Though usually benign, up to 20% of these nodules are found ultimately to be cancerous.
- **Non-diagnostic**, usually because not enough cells are obtained. If repeated, up to 50% of these cases will be able to be diagnosed as benign, cancerous, or suspicious.

One of the most difficult problems for a pathologist is to be confident that a follicular adenoma — usually a benign nodule—is not a follicular cell carcinoma or cancer. In these cases, it is up to the physician and the patient to weigh the option of surgery on a case-by-case basis, with less reliance on the pathologist's interpretation of the biopsy. It is also important to remember that there is a small (3%) risk that a benign nodule diagnosed by fine needle aspiration may still be cancerous. Thus, even benign nodules should be followed closely by the patient and physician. Another biopsy may be necessary, especially if the nodule is growing. While most thyroid cancers are not very aggressive, that is, they do not spread rapidly, the exception is poorly differentiated (anaplastic) carcinoma, which spreads rapidly and is difficult to treat.

What is the treatment for thyroid nodules?

Because of the difficulty in distinguishing follicular adenomas from follicular cancers, patients with either of these two types of nodules, other nodules that are highly suspicious for cancerous, and, of course, with definite cancer, should undergo surgery if they are healthy enough to withstand surgery. Most thyroid cancers are curable and rarely cause life-threatening problems. Any nodule not removed needs to be watched closely with an examination and follow-up with the physician every 6-12 months. This follow-up may involve a physical examination, ultrasound examination, or both. Occasionally, a physician may attempt to shrink the nodule by using suppressive doses of thyroid hormone. Some physicians believe that if a nodule shrinks on suppressive therapy, it is more likely to be benign, and if the nodule continues to grow regardless of suppressive therapy, surgery should be considered strongly. The value of suppressive therapy, however, is controversial.

If a nodule is causing hyperthyroidism, it is usually benign. Treatment is aimed at preventing the signs and symptoms of hyperthyroidism such as heart failure, osteoporosis, and rapid heart rate. Treatments include destroying the gland using radioactive iodine (this time with the iodine isotope 131), blocking the production of thyroid hormone with medications, or just following a patient if the hyperthyroidism is mild.

In cases where a nodule is hyperfunctioning and the TSH is minimally suppressed, but the level of thyroid hormones in the blood is not elevated (these patients have "subclinical hyperthyroidism"), treatment is individualized based on the patients' age, the presence of other medical conditions, and patients' preferences.

Thyroid Cancer

What are the types of thyroid cancer?

Each year, more than 12,000 Americans find out they have thyroid cancer. This disease accounts for about 1 percent of all cancers. Thyroid cancer usually responds well to treatment, and many patients can be cured.

There are four major types of thyroid cancer: papillary, follicular, medullary, and anaplastic. Doctors can tell the type of cancer by the way the cells look under a microscope and by the way the tumor grows.

PAPILLARY TUMORS

Papillary tumors develop in cells that produce thyroid hormones containing iodine. The cancer cells, which grow very slowly, form many tiny, mushroom-shaped patterns in the tumor. Doctors usually can treat these tumors successfully, even when cells from the tumor have spread to nearby lymph nodes. Papillary tumors account for about 60 percent of all thyroid cancers.

FOLLICULAR THYROID TUMORS

Follicular thyroid tumors also develop in cells that produce iodine-containing hormones. These tumors have a thin layer of tissue around them, called a capsule. Many follicular tumors can be cured. However, the disease can be difficult to control if the tumor invades blood vessels or grows through the capsule into nearby structures in the neck. About 17 percent of all thyroid cancers are follicular tumors.

MEDULLARY TUMORS

Medullary tumors affect thyroid cells that produce a hormone that does not contain iodine. Although these tumors grow slowly, they may be harder to control than papillary and follicular tumors. The cancer cells tend to spread to other parts of the body. Only about 5 percent of all thyroid cancers are medullary tumors. It is estimated that 1 out of 10 medullary thyroid cancers is hereditary.

ANAPLASTIC TUMORS

Anaplastic tumors are the fastest growing thyroid tumors. The cancer cells, which are extremely abnormal, spread rapidly to other parts of the body. Anaplastic tumors make up about 18 percent of all thyroid cancers and usually occur in people over 60 years of age.

What causes thyroid cancer?

Doctors do not know what causes most cases of thyroid cancer. However, scientists have observed that thyroid cancer affects women two to three times as often as men and occurs more frequently in whites than in blacks. Scientists do not fully understand the reasons for these patterns; they continue to study thyroid cancer to try to learn what may increase a person's risk for this disease.

One known risk factor is exposure to radiation during childhood. Before doctors knew of its dangers, radiation therapy was used to treat acne and to reduce swelling and infection in organs such as the thymus, tonsils, and lymph nodes. People who received radiation to the head and neck as children have a higher- than-average risk of developing thyroid cancer many years later. Scientists are doing studies to determine whether other types of radiation exposure also can cause thyroid cancer.

Can thyroid cancer be detected early?

The National Cancer Institute recommends that anyone who received radiation to the head or neck in childhood be examined by a doctor every 1 to 2 years. Also, people should see a doctor if they have a family member with medullary thyroid cancer. The most important part of a checkup is the careful examination of the neck, feeling for lumps in the thyroid and enlargement of nearby lymph nodes. A thyroid scan (scintigram) or ultrasonography may be recommended for people at risk for thyroid cancer.

What are symptoms of thyroid cancer?

The most common symptom of thyroid cancer is a lump, or nodule, that can be felt in the neck. Other symptoms are rare. Pain is seldom an early warning sign of thyroid cancer. However, a few patients have a tight or full feeling in the neck, difficulty breathing or swallowing, hoarseness, or swollen lymph nodes. These symptoms can be caused by thyroid cancer or by other, less serious problems. If a person is experiencing symptoms, a doctor should be consulted.

How is thyroid cancer diagnosed?

The doctor can use several tests to learn the size and location of a thyroid nodule and/or to help determine whether a lump is benign (not cancerous) or malignant (cancerous). For example, the doctor may order blood tests to check how well the patient's thyroid is functioning. Also, a radioactive iodine scan can outline abnormal areas of the thyroid. For the scan, the patient is given a very small amount of a radioactive substance (usually iodine I-131 or technetium TC-99m), which collects in the thyroid. An instrument called a scanner can detect "cold spots" (areas in the thyroid that do not absorb iodine normally). Because cold spots can be benign or malignant, further tests are necessary.

Ultrasonography is another technique for producing a picture of the thyroid. In this procedure, high-frequency sound waves, which cannot be heard by humans, pass into the thyroid. The patterns of echoes produced by these waves are converted into a picture (sonogram) by a computer. Doctors can tell whether nodules are fluid-filled cysts, which are usually benign, or solid lumps that might be malignant.

The only sure way to tell whether a patient has thyroid cancer is to look at cells from the thyroid with a microscope. There are two ways to obtain a sample of thyroid tissue: by withdrawing cells using a needle (needle biopsy) or by surgically removing the tumor (surgical biopsy). In either case, a pathologist examines the tissue under a microscope to look for cancer cells.

If the needle biopsy does not show cancer, the doctor may give the patient thyroid hormones. These hormones make it unnecessary for the thyroid to produce its own hormones, and the gland, including the nodule, shrinks and becomes inactive. If the needle biopsy is not conclusive or if the thyroid hormones are not effective, the patient usually has a surgical biopsy.

When thyroid cancer is diagnosed, doctors may do more tests to learn about the stage (extent) of the disease. The results of these tests help doctors plan appropriate treatment.

What treatment is there for thyroid cancer?

Surgery is the most common form of treatment for thyroid cancer that has not spread to distant parts of the body. The surgeon usually removes part or all of the thyroid and any other affected tissue, such as lymph nodes. (If the patient has a surgical biopsy, the biopsy and the removal of the thyroid may be done in the same operation).

Patients with localized papillary or follicular thyroid cancer also may receive treatment with I-131 (a larger dose than that used in a thyroid scan). The patient swallows the iodine, which collects in any thyroid cancer cells that remain in the body after surgery. By damaging such cancer cells, the radioactive iodine helps prevent the disease from recurring. The patient must remain in the hospital for a few days while the radiation is most active. The treatment may be repeated at a later time.

Hormones usually are given to patients who have had surgery to remove the thyroid and/or treatment with radioactive iodine. The hormones replace those that are normally produced by the thyroid. This treatment also slows down the growth of any remaining thyroid cancer cells. The doctor may need to do follow-up tests to determine whether the patient is receiving the proper amount of the necessary hormones.

Surgery may not be recommended when a patient is found to have thyroid cancer that has spread. Treatment usually includes some form of systemic therapy (treatment that can kill or slow the growth

of thyroid cancer cells throughout the body), such as chemotherapy, radioactive iodine therapy, and/or hormone therapy.

Regular follow-up is very important after treatment for thyroid cancer. Follow-up care may include periodic complete physician exams, x-rays, scans, and blood tests.

Thyroid Nodules at a Glance

- Thyroid nodules are the most common endocrine problem in the United States.
- The vast majority of thyroid nodules are benign.
- Individuals with thyroid nodules at the extremes of age, and males with thyroid nodules have a higher likelihood of having a cancerous nodule. Exposure to radiation also increases the probability that a nodule is cancerous.
- Cancer is more of a concern with a solitary nodule than with multiple nodules.
- A nodule in a normally-functioning gland is more likely to be cancerous than a nodule in a gland that is hyperfunctioning.
- A diagnosis of thyroid cancer is aided by ultrasound and radionuclide scanning, but is best made by fine needle aspiration. Caution should be used, however, since there is a possibility that the aspiration may give an incorrect diagnosis or be unable to make a diagnosis (non-diagnostic aspirate).
- Nodules that are hyperfunctioning require treatment aimed at controlling the signs and symptoms of hyperthyroidism.
- Cancerous nodules or those that are highly suspicious for cancer should be removed, while the rest should be followed closely and reassessed frequently.

Thyroid Cancer At A Glance

- The thyroid gland produces thyroid hormones which are important in the normal regulation of the metabolism of the body.
- There are four major types of thyroid cancer.
- The cause of thyroid cancer is unknown, but certain risk factors have been identified.
- The National Cancer Institute recommends that anyone who received radiation to the head or neck in childhood be examined by a doctor every 1 to 2 years.
- The most common symptom of thyroid cancer is a lump, or nodule, that can be felt in the neck.
- The only certain way to tell whether a thyroid lump is cancer is by examining the thyroid tissue obtained using a needle or surgery for biopsy.
- Surgery is the most common form of treatment for thyroid cancer that has not spread to other areas of the body.

For additional information about cancer, write to the Office of Cancer Communications, National Cancer Institute, Bethesda, MD 20892, or call the Cancer Information Service toll free at 1-800-4-CANCER. Spanish-speaking staff members are available.

© 1996-2005 MedicineNet, Inc. All rights reserved. [Copyright and Legal Disclaimer.](#)

Information on this web site is provided for informational purposes only and is not a substitute for professional medical advice. You should not use the information on this web site for diagnosing or treating a medical or health condition. You should carefully read all product packaging. If you have or suspect you have a medical problem, promptly contact your professional healthcare provider.

Statements and information regarding dietary supplements have not been evaluated or approved by the Food and Drug Administration. Please consult your healthcare provider before beginning any course of supplementation or treatment.